

## Histological and immunohistochemical study of thyroid gland in Caucasian squirrel (*Sciurus anamalus*) (Gmelin, 1778) by using marker (Anti-Thyroglobulin, Code IR5090)

Noor Mohammed Jaafer Hammodi<sup>1</sup>, Rana Alaa Al Aamery<sup>2</sup>

<sup>1,2</sup> Department of Biology, College of Education for Pure Science (Ibn Al-Haitham), University of Baghdad, Iraq

### ABSTRACT

The current study is designed to investigate the histological and immunohistochemical characteristics of the thyroid gland in adult male *Sciurus anamalus*. This study found that the thyroid gland of the Caucasian squirrel is located in the neck area, below the larynx, on both sides of the trachea. It has two lobes (right and left) with cylindrical shape. The histological studies revealed that the thyroid gland is surrounded by a capsule which consists of connective tissue and forming of two layers which are outer layer and inner layer, and a layer of adipose tissue appears overlapping the outer layer. The inner tissue of the gland consists of follicles with different shapes and sizes, and is lined with simple cuboidal epithelial tissue (follicular cells). Sometimes it appears in the form of high or low cuboidal epithelial tissue, in dependent on the functional activity state of the gland, and the follicles cavities are filled with colloid. In addition, there are two kinds of cells spread in the gland tissue, follicular cells and parafollicular cells, and they are fewer in number and larger in size than follicular cells and appear either singly or in the form of clusters and occupy two sites between the follicles or within the follicle. Immunologically, the results observed an immune response to thyroglobulin antibodies to detect the protein secreted by the follicular cells, which in turn secreted it to the colloid. Moreover, the immune response appeared clear in the cell membrane of the follicular cells and the colloid through the appearance of the brown color which is specific to the immune reaction.

**Keywords:** First keyword, Second keyword, Third keyword, Fourth keyword, Fifth keyword

### Corresponding Author:

Noor Mohammed Jaafer Hammodi  
Department of Biology, College of Education for Pure Science (Ibn Al-Haitham)  
University of Baghdad, Iraq  
Baghdad, Iraq  
E-mail: [Noor.m@ihcoedu.uobaghdad.edu.iq](mailto:Noor.m@ihcoedu.uobaghdad.edu.iq)

### 1. Introduction

The *Sciurus anamalus* belongs to the family of Sciuridae and order of Rodentia and there are about 50 genera and 273 diagnosed species. It is a mammal that lives on the trees and feeds on bark and tree buds, different types of seeds, and even on fungi found in the forest [1]. The thyroid gland is the largest endocrine gland in the body and is specialized in the production, storage and release of hormones (T3, T4) which regulate the essential metabolic rate in the body [2]. The thyroid gland consists of two lobes on both sides of trachea connected by a narrow isthmus [3]. Each lobe is coated with a capsule consists of dense connective tissue and extends from the capsule a septa inside the gland that support it and make its structure, which is in the form of continuous amounts of connective tissue that contain a network of blood and lymphatic vessels and nerves. The gland is divided into several lobules. The parenchyma of the gland consists of a group of different follicles in shape and size, which represent the functional and structural unit of the gland [4]. The follicular cells or primary cells, which are cuboidal epithelial cells are lined the follicles, and each follicle contains a cavity filled with a colloid material containing the secretions of the follicular cells. Moreover, these cells secrete calcitonin hormone, which is responsible for regulating the level of calcium in the body [5]–[7]. The previous sources showed there are few of research related to the histological and immunohistochemical of thyroid gland structure in Iraqi mammals, with the exception of several studies, including Hussein and Al-Taay's study on Iraqi buffaloes [8], Ali's study



[9] on the local female donkey and Nasser's study on the local rabbits [10]. Therefore, this study aimed to study the thyroid gland in the Caucasian squirrel (*Sciurus anomalus*), which will provide a detailed description the histological and immunohistochemical structure of thyroid gland.

## 2. Material and Methods

### 2.1. Samples collections

The study samples represented by the thyroid gland were collected from 6 animals of adult male *Sciurus anomalus*, which were obtained from the local markets in Baghdad governorate. All samples were classified according to the taxonomic key in the Museum of Natural History in Baghdad. The animals were dissected and the thyroid gland location was specified and then it was removed and the sample was fixed in formalin solution (10%) in order to use it in the histological study.

### 2.2. The Histological preparations

The Samples fixed using 10% of formalin to prepare all specimens for the histological study. The samples are passed through an ascending series of alcohols including 70, 80, 90 and 100%, then the samples are clarified with xylene and embedded in paraffin wax blocks. The blocks of paraffin wax were then cut using microtome to produce sections with 6 mm in thickness. The obtained section were stained with Haris Haematoxlin and Eosin stain [11], [12]. The immunological reaction was performed using the marker (Anti-Thyroglobulin, Code IR5090) and determined by the presence or absence of dye in the tissue and in the case of an immune response present, symbolized by (+) which is represented by the appearance of a brown color in tissue cytoplasm, whereas the absence of the reaction was represented by (-) symbol. Then, the slides were examined using a photographed microscope connecting to the digital camera which used to capture images of the chosen sections.

## 3. Results

### 3.1. The Morphological description of the thyroid gland

The results of the anatomical examination observed that the location of thyroid gland in adult male (*S. anomalus*) is in the neck area beneath the larynx on both sides of the trachea. It consists of two lobes, and absence of the isthmus that connects the two lobes, as in other mammals. In addition, the gland appears cylindrical, elongated with reddish-brown in color, and the right lobe is a little longer than the left (Fig. 1).

### 3.2. The Histological structure of the thyroid gland

The microscopic examination results of thyroid gland in male *Sciurus anomalus* revealed that it is surrounded by a capsule which consists of connective tissue and forming of two layers, outer and inner layer, in addition to a layer of fatty tissue overlapping with the outer layer. The outer layer consists of colloidal and elastic fibers and a few reticular fibers and is also interspersed with fibroblasts. As for the inner layer, it contains colloidal fibers, smooth muscle fibers, blood vessels and nerves; this layer is connected to the inner tissue of the gland through septa dividing it into several lobules (Fig. 2). In addition, the gland tissue consists mainly of follicles, which appeared in different shapes, including circular, oval, polygonal, and others with irregular shape, and also with different sizes, large, medium and small, distributed randomly within one lobe (Fig. 3). The simple cuboidal epithelial tissue is lined the follicles that appears sometimes high or low, in dependent to the functional activity state of the gland. There are two kinds of cells spread in the gland tissue, follicular and parafollicular cells. The follicular cells are with the spherical nuclei in shape; these cells are based on the basement membrane, which can be seen clearly using (PAS) stain. On the other hand, the parafollicular cells range in shape from rounded to polygonal shape, and the nuclei are spherical in shape and large in size. Moreover, the cytoplasm is clear and transparent and did not appear to be receptive to dyes, while the calcitonin cells (C-cells) can be distinguished using hematoxylson-eosin (H&E) stain, and they appear singly or in the form of clusters. These cells occupy two locations between the follicles or within a single follicle, and their surface touches the colloidal substance (Fig. 4).

The follicles contain cavities filled with a gelatinous substance, which is the colloidal substance, which appear in varying quantities in the follicles; they may appear completely filled, while some contain small amounts, and others are completely empty. The colloid is able to stain with PAS dye because it contains glycoproteins and appears in a violet color and also appears in a light pink color using hematoxylin and eosin stain (Fig. 5). Additionally, in the connective tissue between the follicles, there is a supporting network of blood vessels, lymphatics, and nerves.

### 3.3. The immunohistochemically study

The results of the study detected an immune response with varying intensity to (Anti- Thyroglobulin , Code IR5090) marker to detect the protein secreted by the follicular cells, which in turn secreted it to the colloid. Furthermore, the immune response of the cell membrane in the follicular cells was appeared through the presence of the brown color of the immune reaction with varying intensity (++) and (+++) (Fig.6), while the colloid showed a strong immune response and intensity (+++) (Fig.7), while the parafollicular cells did not show a clear immune response (-). The follicular cells produce thyroglobulin and secrete it into the colloid, which helps in capturing iodine in order to produce thyroid hormones.

### 4. Discussion

The findings of the anatomical examination revealed that the thyroid gland in adult male Caucasian squirrels (*S. anamalus*) consists of two lobes located in the neck area below the larynx on both sides of the trachea, in addition to the absence of the isthmus that connects the two lobes, as it appeared in other mammals. This is consistent with previous researches, including the results of the thyroid gland in wild African grass cutter [13], The mice (*Swiss albicans*) [14], weasel (*Herpistus javanicus*) [15], the long-eared hedgehog (*Hemichenus auritus*) [16], and guinea pigs [17]. On the other hand, there are studies indicating the presence of the isthmus structure that connecting the two thyroid lobes, as in local female donkey [9], local Iraqi sheeps [18] and one-campus camel [19]. While in other studies, as in dolphins, 41% of them detected the presence of the isthmus and 28% lacked the isthmus [20]. This contradicts the results of the current study in the Caucasian squirrel may due to the different metabolic activity in different mammals, or due to the functional need and the nature of the environment for both. In the current study, The two thyroid lobules in the *S. anamalus* appear in different sizes, and these observations are in agreement with the findings of previous studies, including the African giant rat [21], gray mongoose [22] and Bakerwali goat [23]. While these results differed with the study of [24] on Belarusian hedgehog, in which the size of the right lobe is similar to the size of the left lobe. The reason for the difference in size is may due to the difference in age, sex, as well as the activity of the animal depending on the functional need [13], [25]. In contrast, the color of the gland is similar to what was found in the previously mentioned studies. Histologically, the microscopic examination results revealed that the thyroid gland is coated by a capsule consists of two layers of connective tissue, in addition to a layer of fatty tissue interfering with the outer layer of the capsule. These results are in agreement with the study of the thyroid gland in Iraqi buffalo [8], gazelles and sheeps [26], guinea pigs (Guniea pigs), and albino rats [17]. On the other hand, the results of this study regarding the capsule for both animals did not agree with the findings of the study of the thyroid gland in the African giant rat [27] and white hybrid pigs [25], where it was found that the capsule is consist of a single layer of connective tissue. Furthermore, it did not agree with the study on black Bengal goat thyroid gland [28] and rabbits [29], as the capsule was found to be composed of three layers: inner layers and outer layer consisting of connective tissue and middle layer consisting of fatty and nervous tissue. The reason for the difference in the results of this study with the previous studies mentioned above may be due to the need for energy to accomplish the function and to the different nature of the environment as well as the variation in the sizes of animals.

The findings of the current study observed that the inner gland tissue consists of different follicles in size and shape, and this is consistent with the studies of the Iraqi buffalo [8], the wild African grass-catter [13] and the giant rat. African [21], weasel (*Herpestes javanecus*) [15], and long-eared hedgehog (*Hemiechinus auritus*) [16]; this similarity is certainly due to the nature of function and secretory activity of its cells. Interestingly, the microscopic examination found a variation in the tissue lining the follicles, as the follicles are lined with either low simple cuboidal epithelial tissue or high simple cuboidal epithelial tissue, and the epithelial tissue lining the follicles is based on a basement membrane. The results of this study regarding the tissue lining the thyroid follicles are in agreement with previous on in Ewes [30], The mice (*Swiss albicans*) [14] and Belarusian hedgehog (*Belarus Hedgehog*) [24], which are observed that the follicles lining is composed of simple cuboidal epithelial tissue. In contrast, the observed results is not agree with the study on West African dwarf goat [31] where the lining is consist of simple cuboidal epithelial tissue and simple squamous epithelial tissue, while in the one-humped camel [19] the follicle is lined with varying epithelium from simple cubic epithelium to simple low columnar epithelium. The incompatibility is due to the difference in the gland activity in different mammals, where the diversity in the sizes of the follicles and the height of the epithelium indicates the gland follicles activity, where the activity is inversely proportional to the follicle diameter [6].

There are cells called parafollicular cells spread in the gland tissue or called calcitonin cells or (C-cells); these results are in agreement with a number of studies, including the study of the thyroid gland in the weasel (*Herpestes javanecus*) [15], long-eared hedgehog (*Hemiechinus auritus*) [16], adult male guinea pigs (*Cavia*

*porcellus*), and albino rats (*Rattus norvegicus*) [17]. The previous studies indicated that follicular cells occupy two positions, either intrafollicular position or interfollicular position, which are the study of the thyroid gland in the black goat Bengal [28], the African giant rat [21], the Belarusian hedgehog [24], and the European bison [32]. However, this study did not agree with the study conducted on the one-humped camel, in which the parafollicular cells did not appear within the gland tissue [19]. The difference in the numbers of C-cells and their spread within the gland tissue may indicate the histological composition, the environment of the animal, and the nature of the function of the cells. C-cells act to balance the calcium in the blood, and its rise leads to the release of the calcitonin hormone from the cell, which in turn inhibits the absorption of calcium by the intestines, causing an inhibiting in the action of osteoclast cells, thus reducing calcitonin in the blood [33]. The follicles cavities appear filled with a gelatinous substance, which is the colloid, and its quantity varied within the follicle, and this is consistent with the studies of [34] in bat (*Taphozous kacchensis*), gazelles and sheeps [26]. The colloid is stained with violet color as it appears more receptive to PAS dye (PAS-positive) than other colourants. This result is consistent with the study of mice (*Swiss albican*), (14) in male rabbits, white crossbred pigs and white cattle [35]. The reason for the strong interaction of the colloid with the PAS dye is that the thyroglobulin secreted by the thyroid gland contains 2-4% of hexosamine, as well as galactose, mannose, fructose and other carbohydrates, as well as thyroglobulin contains various iodinated amino acids [36]. The immunological study included using (Anti- Thyroglobulin , Code IR5090) marker in this study; the results showed an immune response to thyroglobulin antibodies to detect the protein secreted by the follicular cells, which in turn secreted it to the colloid. Moreover, the immune response appeared clear to the cell membrane of follicular cells and colloid through the appearance of the brown color of the immune reaction. The results of this study were consistent with the study on dogs [37], in which the thyroglobulin marker was used to detect tumors, as it showed a clear immune response to the proteins found in colloid. Furthermore, a strong response was detected in horses [38], guinea pigs (*Cavia porcellus*) [39] and humans that used this marker to detect adenocarcinomas that present difficulties in diagnosis [40].

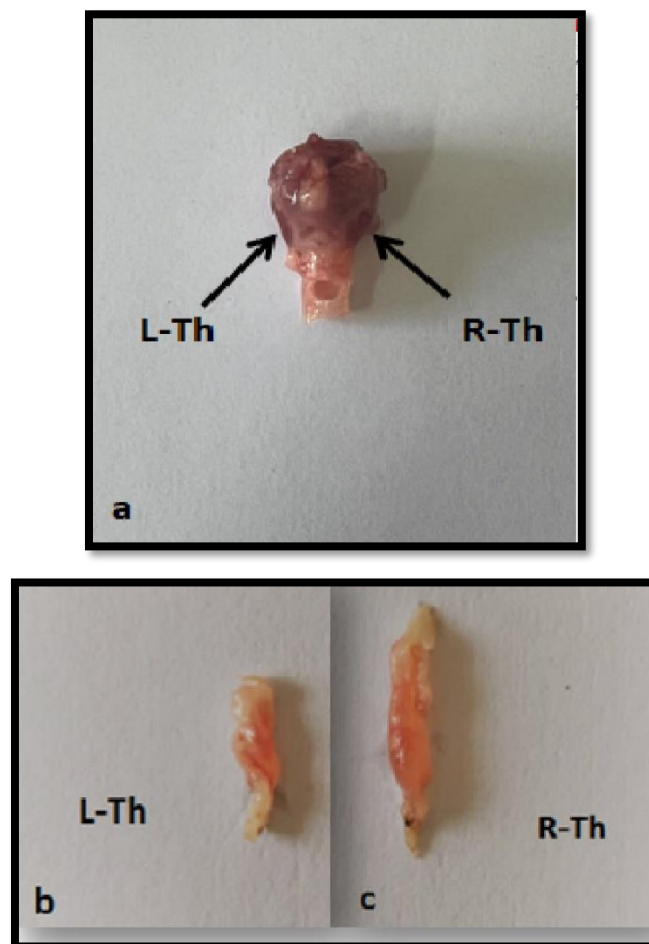


Figure 1. a. Positon of thyroid gland in *Sciurus anomalus* (T) trachea, b. (L.Th ) left thyroid lobe , c. (R.Th ) right thyroid lobe

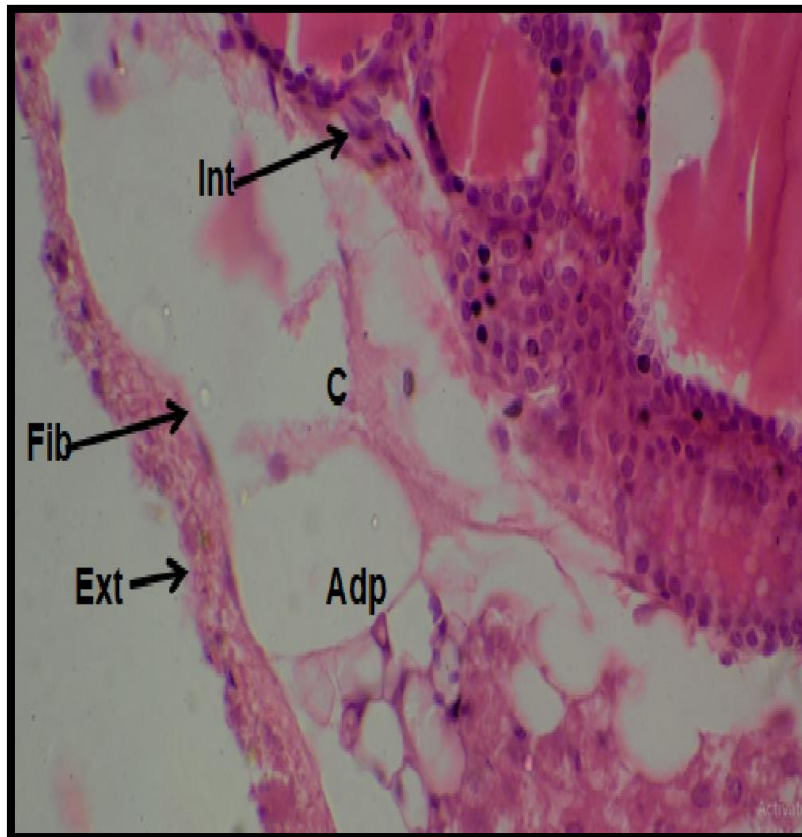


Figure 2. Cross section in thyroid gland showing (c) capsule , (Ext) external layer of capsule (Int) internal layer of capsule , (Adp) adipose tissue , (Fib) fibroblast (H&E stain, 40X)

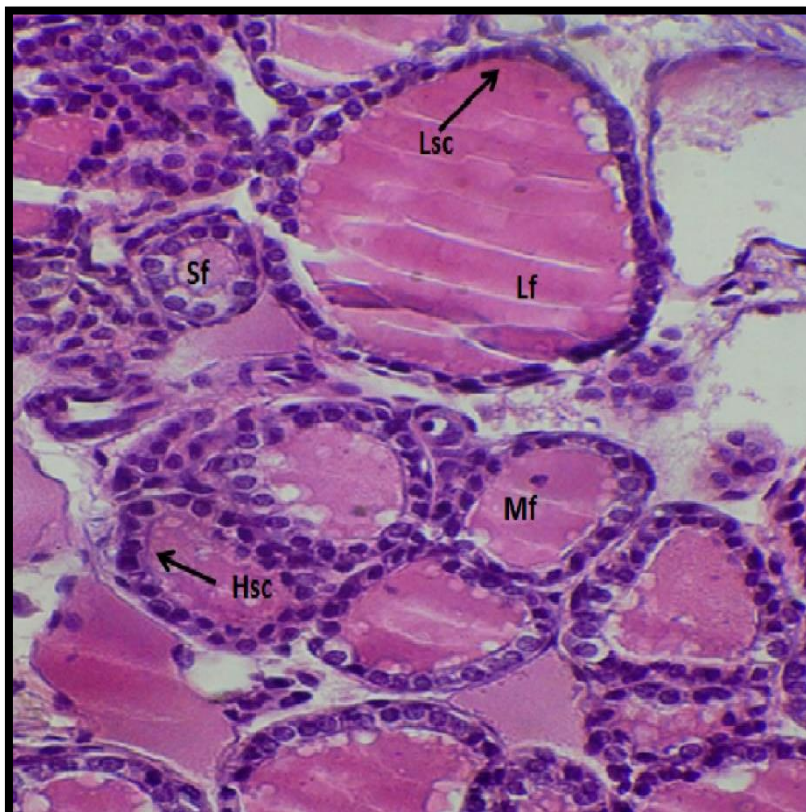


Figure 3. cross section in thyroid gland showing ( Lf) large follicle , (Sf) small follicle, (Mf) medium follicle, (Hsc) high simple cuboidal epithelial tissue , (Lsc) low simple cuboidal epithelial tissue (PAS stain, 40X)

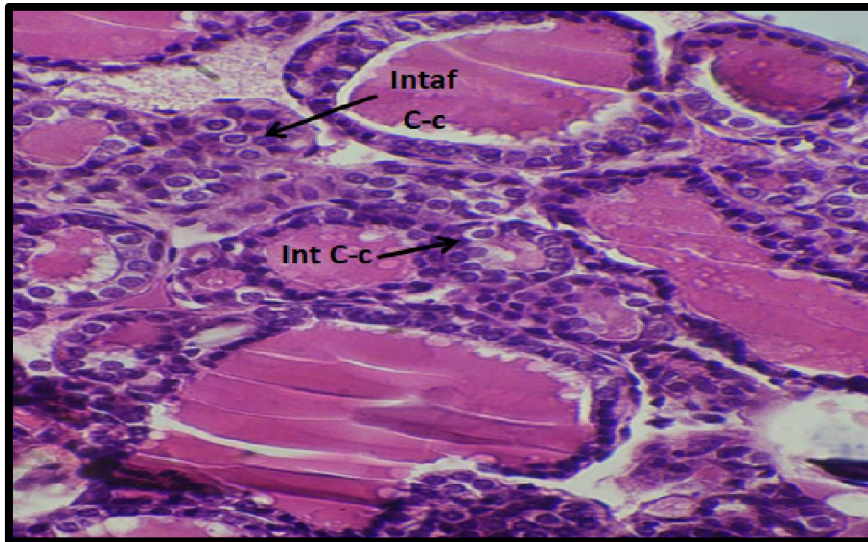


Figure 4. cross section of thyroid gland showing (Intaf C-c) intra follicles parafollicular cell , (Int C-c) inter follicles parafollicular cells (PAS stain, 40X)

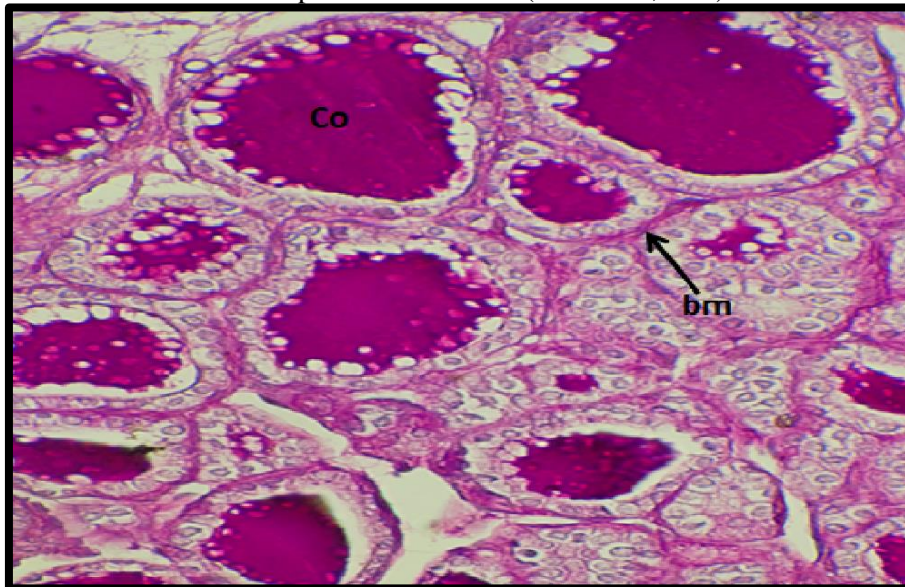


Figure 5. cross section of thyroid gland showing, (bm) basement membrane , (Co) colloid (PAS stain, 40X)

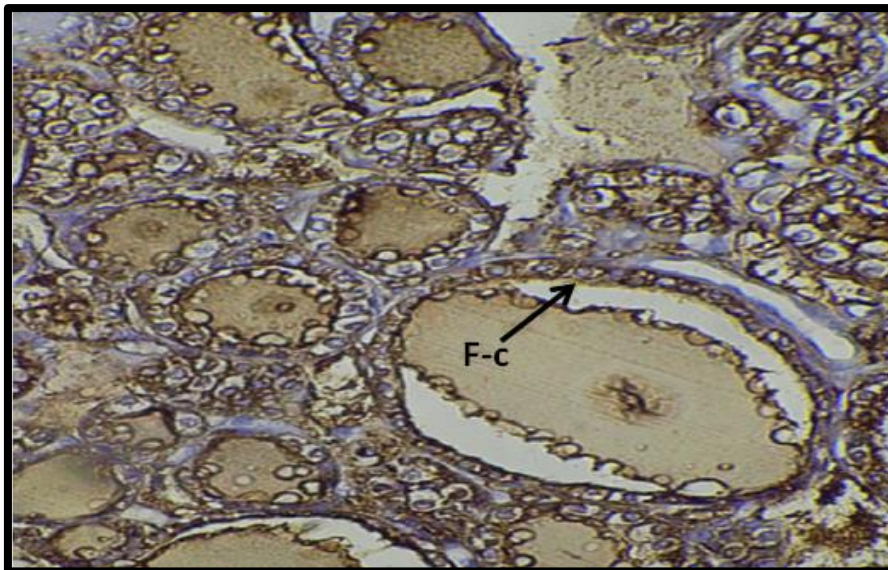


Figure 6. cross section of thyroid gland showing, (F-c) Follicle cell (Anti thyroglobulin marker,40X)

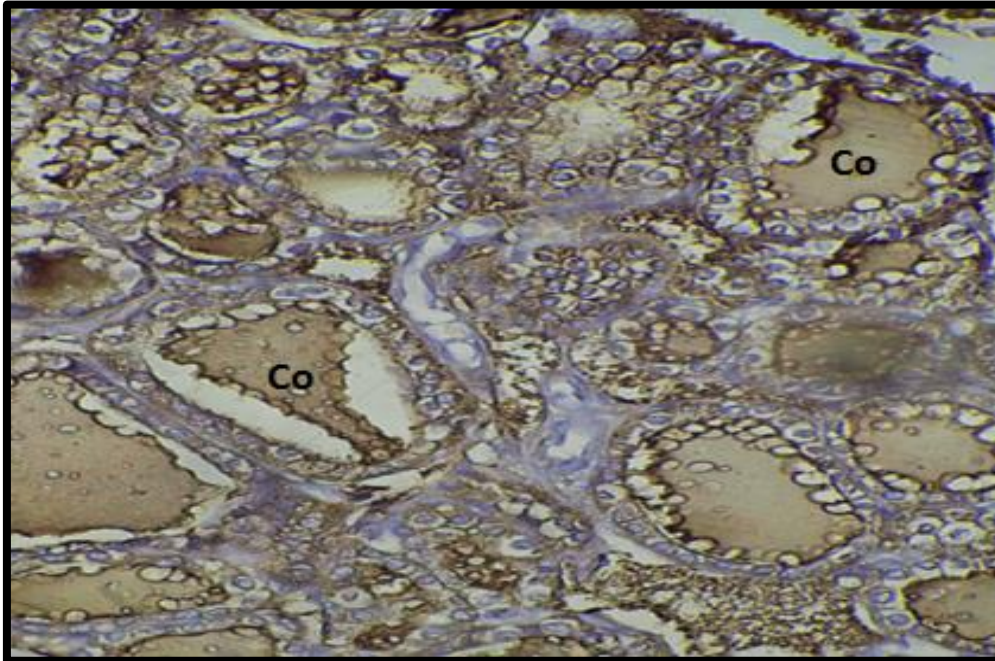


Figure 7. A cross section in thyroid gland showing, (Co) colloid (Anti thyroglobulin marker , 40X)

## 5. Conclusion

This study revealed that thyroid gland in male *Sciurus anamalus* is consists of two lobes (right and left) and it is surrounded by a capsule of two outer and inner layers. The histological composition of the thyroid gland consists of several follicles; the follicles are lined with simple cuboidal epithelium tissue. The thyroid gland is composed of two kinds of cells including epithelial cells and (C-cells). Some follicles are filled by colloid while others contain a lesser amount of it. The immune response of the cell membrane in the follicular cells was appeared through the presence of the brown color of the immune reaction with varying intensity (++) and (+++), while the colloid showed a strong immune response and intensity (+++), while the parafollicular cells did not show a clear immune response.

## Conflict of Interest

The authors declare no conflicts of interest.

## Funding

This research received no specific grant from any funding

## References

- [1] R. W. Thorington Jr and K. Darrow, "Anatomy of the squirrel wrist: bones, ligaments, and muscles," *Journal of Morphology*, vol. 246, no. 2, pp. 85–102, 2000.
- [2] A. A. Tira, "Translate from Hewer, E. Histology for medical students," *Baghdad national library*, p. 863, 1977.
- [3] V. Eroschencho, "Atlas of histology with functional correlations," *Williams and Wilkins Lippincott*, vol. 11, 2005.
- [4] K. V. Kardong, *Vertebrates: comparative anatomy, function, evolution*, 4th ed. Washington state university, 2006.
- [5] M. Ruchala, E. Szczepanek, P. Sujka-Kordowska, M. Zabel, M. Biczysko, and J. Sowinski, "The immunohistochemical demonstration of parafollicular cells and evaluation of calcium-phosphate balance in patients with thyroid hemiagenesis," *Folia Histochemica et Cytobiologica*, vol. 49, no. 2, pp. 299–305, 2011.
- [6] K. Al-Mukhtar and A. A. AL-Rawi, *Histology*, 2nd ed. Dar al- kutub for Printing and Publishing, Baghdad, 2000.

- [7] A. Borda, N. Berger, M. Turcu, M. Al Jaradi, and S. Veres, "The C-cells: current concepts on normal histology and hyperplasia," *Rom J Morphol Embryol*, vol. 4, pp. 53–61, 2004.
- [8] A. M. Hussin and M. M. Al-Taay, "Histological study of the thyroid and parathyroid glands in Iraqi buffalo " bubalus bubalis" with referring to the seasonal changes," *Bas. J. Vet. Res*, vol. 8, no. 1, pp. 26–38, 2009.
- [9] S. Ali, "Anatomical and histological study of thyroid gland in female local donkeys (Eqws africanus asinus) at Basrah city," *Al-Qadisiyah Journal of Veterinary Medicine Sciences*, vol. 13, no. 1, pp. 85–87, 2014.
- [10] R. Abd Alameer Nasser, "ANATOMICAL AND HISTOLOGICAL STUDY OF THETHYROID GLAND INRABBIT (ORYCTOLAGUS CUNICULUS)," *Basrah journal of veterinary research*, vol. 11, p. 4, 2014.
- [11] J. D. Bancroft and M. Gamble, *Theory and practice of histological techniques*, 6th ed. Elsevier health sciences, 2008.
- [12] G. L. Humason, "Animal tissue techniques.," *Animal tissue techniques.*, 1979.
- [13] C. Igbowe, "Gross and microscopic anatomy of thyroid gland of the wild African grasscutter (Thryonomys swinderianus, Temminck) in Southeast Nigeria," *Eur. J. Anat*, vol. 14, no. 1, pp. 5–10, 2010.
- [14] A. M. Hussin and Y. Y. Khudhayer, "A COMPARATIVE HISTOLOGICAL STUDY OF THYROID TISSUE IN CARP FISH CYPRINUS CARPSIO AND MICE SWISS ALBICANS," *Bulletin of the Iraq Natural History Museum (P-ISSN: 1017-8678, E-ISSN: 2311-9799)*, vol. 14, no. 2, pp. 109–116, 2016.
- [15] R. A. Al-Aamery and H. A. Dauod, "Anatomical and Histological Study of Thyroid Gland in Weasel (Herpestes javanicus)(E. Geoffroy saint. Hilaire, 1818)," *Ibn AL-Haitham Journal For Pure and Applied Science*, vol. 29, no. 1, 2016.
- [16] R. A. Al-Aamery and H. A. Dauod, "Anatomical and Histological Study of Thyroid Gland in Hedghoge (Hemiechinus auritus) (Gmelin, 1776)," *Ibn AL-Haitham Journal For Pure and Applied Science*, vol. 8, no. 1, pp. 133–145, 2016.
- [17] A. Batah and S. Mirhish, "Comparative Histomorphological and Histochemical Study of Thyroid Gland in Adult Males of Guinea Pigs (Cavia porcellus) and Albino Rats (Rattus norvegicus) \*Address for Correspondence," May 2019.
- [18] M. A. Ali, A. H. Sadoon, A. Samera, and A. Sawsan, "Anatomical and histological study of thyroid gland in local Iraqian sheep," *Journal of International Academic Research for Multidisciplinary*, vol. 3, no. 3, pp. 195–200, 2015.
- [19] S. J. Ahmadpanahi, "Presence of the Parafollicular Cells in the Thyroid Gland of the One-Humped Camel.," *Acta Veterinaria Eurasia*, vol. 45, no. 2, pp. 37–42, 2019.
- [20] D. Cowan and Y. Tajima, "The thyroid gland in bottlenose dolphins (Tursiops truncatus) from the Texas coast of the Gulf of Mexico: normal structure and pathological changes," *Journal of Comparative Pathology*, vol. 135, no. 4, pp. 217–225, 2006.
- [21] F. Enemali, J. Hambolu, J. Alawa, and I. Anosike, "Gross Anatomical, Histological and Histochemical Studies of Thyroid Glands of African Giant Rat (Cricetomys gambianus Waterhouse, 1840)," *IOSR Journal of Pharmacy and Biological Sciences*, vol. 11, no. 4, pp. 40–43, 2016.
- [22] M. Tadjalli and A. Faramarzi, "Gross Anatomy of the Thyroid and Parathyroid Glands in Indian Gray Mongoose, (Herpestes Edwardsii)," vol. 5, no. 1, pp. 1–5, 2016.
- [23] Y. Dar, S. Suri, K. Sarma, and J. Singh, "Gross Morphological and Biometrical Studies on Thyroid Gland in Bakerwali Goat ( Capra hircus )," *Applied Biological Research*, vol. 20, p. 209, Jan. 2018, doi: 10.5958/0974-4517.2018.00027.7.
- [24] D. Fiadotau, "Anatomy and histology of thyroid gland of the hedgehog (erinaceus concolor) in belarus," *Biological Markers in Fundamental and Clinical Medicine (collection of abstracts)*, vol. 1, no. 4, pp. 63–64, Dec. 2017, doi: 10.29256/v.01.04.2017.escbm22.
- [25] C. Igbokwe and D. Ezeasor, "Histological and immunohistochemical changes of the thyroid gland during the foetal and post-natal period of development in indigenous large white crossbred pigs," Jan. 2015.
- [26] E. Khalel and A. M. Salih, "Comparative histomorphological and histochemical study of thyroid gland in adult indigenous gazelle (Gazella subgutturosa) and sheep (Ovis aries)," vol. 5, no. 6, pp. 1236–1241, Jan. 2017.
- [27] I. Casmir and D. Ezeasor, "LIGHT AND ELECTRON MICROSCOPIC STUDY OF THE THYROID GLAND OF THE AFRICAN GIANT RAT (CRICETOMYS GAMBIANUS, WATERHOUSE)," *Pakistan journal of zoology*, vol. 46, pp. 1223–1230, 2014.



- [28] G. N. Adhikary, M. A. Q. Quasem, and S. K. Das, "Histological Observation of Thyroid Gland at Prepubertal, Pubertal and Castrated Black Bengal Goat," *Pakistan J. of Biological Sciences*, vol. 6, no. 11, pp. 998–1004, 2003, doi: 10.3923/pjbs.2003.998.1004.
- [29] M. V. Zakrevska and A. M. Tybinka, "Histological structure of the thyroid gland in rabbits with different types of autonomous tonus," *SMLNUVMB*, vol. 22, no. 98, pp. 119–127, 2020, doi: 10.32718/nvlvet9821.
- [30] Z. Peksa *et al.*, "Histometric and biochemical properties of the thyroid gland in sheep with high iodine supplementation," *Acta Vet. Brno*, vol. 82, no. 4, pp. 405–409, 2013, doi: 10.2754/avb201382040405.
- [31] C. O. Igbokwe, D. N. Ezeasor, and M. B. Umar, "Ultrastructure of the Thyroid Gland in Adult West African Dwarf Goat (*Capra hircus*)," *Int. J. Morphol.*, vol. 33, no. 2, pp. 532–537, 2015, doi: 10.4067/S0717-95022015000200020.
- [32] J. Sokolowska, J. Berczynska, A. Poweska, D. Rygiel, K. Olbrych, and K. Urbanska, "Immunohistochemical characteristic of C cells in European bison thyroid gland," *Folia Histochem Cytobiol*, vol. 56, no. 4, pp. 222–230, 2018, doi: 10.5603/FHC.a2018.0024.
- [33] G. J. Cote, E. G. Grubbs, and M.-C. Hofmann, "Thyroid C-Cell Biology and Oncogenic Transformation," *Recent Results Cancer Res*, vol. 204, pp. 1–39, 2015, doi: 10.1007/978-3-319-22542-5\_1.
- [34] D. S. Bansod and A. A. Dhamni, "Changes in the thyroid gland of the male emballonurid bat, *Taphozous kachchensis* (Dobson) during the reproductive cycle," *Int. J. of Life Sciences*, vol. 2, no. 3, pp. 256–262, 2014.
- [35] O. I. Casmir and N. E. Daniel, "Histologic and ultrastructural observations on the thyroid gland of the White Fulani (Zebu) cattle in Northern Nigeria," *Afr. J. Biotechnol.*, vol. 14, no. 2, pp. 156–166, 2015, doi: 10.5897/AJB2014.13678.
- [36] D. W. Fawcett, *Bloom & Fawcett Textbook Of Histology*, 9th ed. London, 1970.
- [37] J. A. Ramos-Vara, M. A. Miller, G. C. Johnson, and L. W. Pace, "Immunohistochemical detection of thyroid transcription factor-1, thyroglobulin, and calcitonin in canine normal, hyperplastic, and neoplastic thyroid gland," *Vet Pathol*, vol. 39, no. 4, pp. 480–487, Jul. 2002, doi: 10.1354/vp.39-4-480.
- [38] T. Oyamada *et al.*, "Immunohistochemical Characterization of Parafollicular Cell Adenoma, Medullary Carcinoma and Follicular Adenocarcinoma in Thyroid of Horses," *JES*, vol. 16, no. 1, pp. 11–17, 2005, doi: 10.1294/jes.16.11.
- [39] P. M. Gibbons, M. M. Garner, and M. Kiupel, "Morphological and immunohistochemical characterization of spontaneous thyroid gland neoplasms in guinea pigs (*Cavia porcellus*)," *Vet Pathol*, vol. 50, no. 2, pp. 334–342, 2012, doi: 10.1177/0300985812447828.
- [40] S. Steurer, J. Schneider, and T. S. Clauditz, "Immunohistochemically detectable thyroglobulin expression in extrathyroidal cancer is 100% specific for thyroidal tumor origin," *Ann Diagn Pathol*, vol. 54, p. 151793, Oct. 2021, doi: 10.1016/j.anndiagpath.2021.151793.